

Diagnosis and treatment of persistent obstructive sleep apnea in children

Diagnostyka i leczenie przetrwałego obturacyjnego bezdechu sennego u dzieci

Department of Pediatric Otolaryngology, Medical University of Warsaw, Poland
Head of Department: Associate Professor Lidia Zawadzka-Głós, MD, PhD

KEYWORDS

children, sleep apnea, OSA, apnea-hypopnea index, AHI, CPAP, sleep endoscopy, DISE

SUMMARY

Unresolved obstructive sleep apnea (OSA) in children following adenoid and/or tonsil removal, referred to as “persistent”, is becoming an increasing concern in the pediatric population. This condition is influenced by various factors, which often overlap. Risk factors for persistence include obesity, severe OSA prior to surgery, specific age groups, as well as certain complex diseases such as trisomy 21. All children who have undergone surgery should be monitored for residual symptoms, and for those who present them, polysomnography should be conducted to identify persistent disease. Upper airway evaluation, including the foremost use of drug-induced sleep endoscopy, can help pinpoint sites of obstruction, guiding subsequent treatment. There is a wide range of both non-surgical and surgical options available to address this issue, but due to its complexity, managing such patients often necessitates a multidisciplinary approach. This study aims to identify the problem, emphasize key considerations, and present various aspects of managing these children.

SŁOWA KLUCZOWE

dzieci, bezdech senny, OBS, wskaźnik bezdechu i sptyczenia oddechu, AHI, CPAP, endoskopia w śnie indukowanym, DISE

STRESZCZENIE

Obturacyjny bezdech senny (OBS) u dzieci, nadal obecny po usunięciu migdałka gardłowego i/lub migdałków podniebiennych, określane jako „przetrwały”, staje się coraz większym problemem w populacji pediatrycznej. Na ten stan wpływają różne czynniki, które często nakładają się na siebie. Czynniki ryzyka przetrwałości obejmują: otyłość, ciężki stopień nasilenia OBS przed operacją, określone grupy wiekowe, a także niektóre złożone choroby, takie jak trisomia chromosomu 21. Wszystkie dzieci, które przeszły operację usunięcia tkanki migdałków, powinny być monitorowane pod kątem objawów resztkowych, a u tych, które je prezentują, należy wykonać polisomnografię w celu zidentyfikowania utrzymującego się OBS. Ocena górnych dróg oddechowych, w tym przede wszystkim endoskopia w śnie indukowanym, może pomóc w określeniu lokalizacji zwężenia dróg oddechowych, co pomaga w ustaleniu dalszego leczenia. Istnieje szeroki wachlarz zarówno niechirurgicznych, jak i chirurgicznych metod rozwiązania tego problemu, ale ze względu na jego złożoność leczenie takich pacjentów często wymaga podejścia multidyscyplinarnego. Niniejsze badanie ma na celu zidentyfikowanie problemu, podkreślenie kluczowych kwestii i przedstawienie różnych aspektów postępowania z dziećmi z przetrwałym OBS.

INTRODUCTION

Obstructive sleep apnea (OSA) in children refers to a sleep-related breathing disorder where there are repeated occurrences of either complete or partial blockages in the upper airway, leading to intermittent periods of reduced oxygen levels and disrupted sleep patterns. It is a common condition that affects 1-4% of children, mostly 2-8 years of age, which correlates with overgrowth of the lymphatic tissue of Waldeyer's tonsillar ring (1).

OSA can lead to several sequelae including mainly cardiovascular, endocrine and neurocognitive complications and subsequently poor quality of life (2). The prevalence of OSA is much higher in children with obesity, craniofacial and neuromuscular disorders as well as other complex comorbidities.

The primary reason for OSA in children is the enlargement of adenoid and tonsils, and the standard approach for addressing this problem remains the surgical removal of tonsillar tissue either with or without the adenoid. However, a significant number of OSA children undergoing extraction of lymphoid tissue exhibit residual persistent OSA post-surgery, especially those with the aforementioned medical complexity.

The aim of this study was to present the diagnostic approach for suspected residual OSA in children aged 2 years and older. Since we have already presented available diagnostic modalities (3) as well as certain treatments (4) for patients with OSA in our previous studies, they will not be widely discussed here. In this specific review, we focus on how to define the problem in such patients, help guide decision-making, highlight key considerations and challenges regarding effective diagnosis and treatment of persistent OSA.

DEFINITION

It is important to note that there is currently no widely accepted definition of persistent OSA. In this review, the term persistent OSA is utilized to describe unresolved OSA in children, with an obstructive apnea-hypopnea index (oAHI – here referred as AHI) of at least 1.5 per hour of sleep, as determined by polysomnography (PSG), following adenotonsillotomy (ATT) or adenotonsillectomy (ATE) (5, 6). In children, AHI of 1-5 events per hour is considered mild OSA, > 5-10 is moderate, and above 10 events is considered severe. The cutoff value of 1.5 is slightly higher than the lower range for mild OSA to prevent overdiagnosis. The data comparing children to adult criteria is shown in table 1.

Tab. 1. Comparison between pediatric and adult criteria for OSA severity

OSA	AHI in children	AHI in adults
Mild	1-5	5-15
Moderate	5-10	15-30
Severe	> 10	> 30

AHI – apnea-hypopnea index

For the purposes of this particular study we established that the result of both surgical approaches are equal and be referred as AT. This topic will also be described further. The prevalence of persistent OSA varies between 13 and 79%, contingent on the criteria employed for defining persistent disease and the characteristics of the study population (7).

Pathophysiology and risk factors

Etiology of persistent OSA is often multifactorial and is a result of altered airflow dynamics in the upper airways. The factors that contribute to persistent OSA may be divided broadly into structural and neuromuscular. Obstruction may be caused by one or more of the upper airway's structures, besides adenoid and tonsils (which is referred as multilevel obstruction). Neuromuscular tone is not addressed during AT, and surgery doesn't affect it. These briefly may be present both together or separately and be the cause of decreased upper airway's patency and therefore results in persistent OSA.

Children at highest risk of persistent OSA are those with obesity, severe OSA, as well as children older than 7 and younger than 3 years of age (8). The specific comorbidities most commonly connected with persistent OSA include among others: Down syndrome (9), Prader Willi syndrome (10) and mucopolysaccharidosis (11).

DIAGNOSTICS

Polysomnography and other sleep studies

The gold standard to diagnose OSA in children is overnight PSG which is a sleep study recommended by most international guidelines for all children when the clinical assessment is suggestive of sleep-disordered breathing (12). In otherwise healthy children some of the guidelines permit usage of alternative testing when polysomnography is not available (7, 13). In patients with high-risk of recurrence and these with residual symptoms following surgery, PSG is favorable. The positions of individual medical societies have been presented in the table 2.

Tab. 2. The position statements of medical societies regarding the diagnosis of persistent obstructive sleep apnea (OSA) in children (based on (14))

Children with persistent OSA following AT – posttreatment re-evaluation of high risk patients
<ul style="list-style-type: none"> • AAP: High-risk children (defined as those with significantly abnormal baseline polysomnogram, sequelae of OSA, obesity, or continued symptoms following treatment) should be reevaluated with objective testing or referred to a sleep specialist (7) • AASM: Polysomnography should be repeated following adenotonsillectomy in children at risk of recurrence (15)
ERS: Patients at risk of persistent OSA or with persistent symptoms should be reevaluated with polysomnography or polygraphy (13)

AAP – American Academy of Pediatrics; AASM – American Academy of Sleep Medicine; ERS – European Respiratory Society

Upper airway evaluation

Drug induced sleep endoscopy (DISE) is an important tool to evaluate factors contributing to persistent OSA. While conducting DISE, a flexible endoscope is inserted to the upper airways during pharmacologically induced sedation, to identify sites of possible obstruction. In children with persistent OSA, they may be located on many levels and include: nasal cavity, nasopharynx (secondary regrowth of adenoid), velum, oropharynx, base of tongue, and supra-glottic larynx (fig. 1, 2).

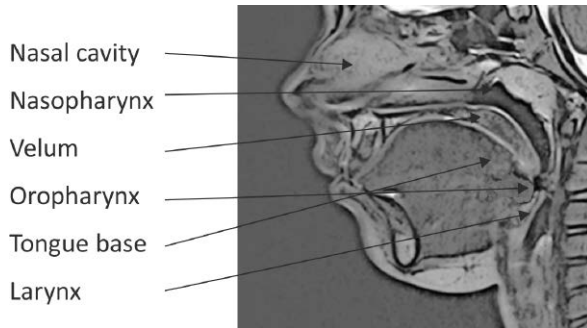


Fig. 1. Possible sites of obstruction visualized during drug-induced sleep endoscopy (DISE)

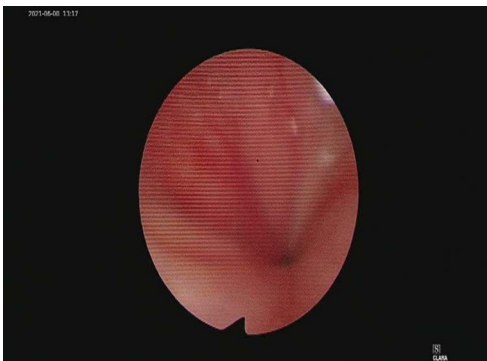


Fig. 2. Concentric collapse at the velum during drug-induced sleep endoscopy (DISE)

During Cine MRI repetitive MRI images are obtained while the patient is in a drug-induced sleep state. The images are combined into a “cine” or movie format which is reviewed for site(s) of obstruction. In a meta-analysis conducted by Socarras (16), both DISE and Cine MRI were found to lead to improvements in persistent pediatric OSA when utilized to guide surgical interventions.

TREATMENT

In the realm of non-surgical management for persistent OSA, it is important to highlight the effectiveness of continuous positive airway pressure (CPAP) therapy. However,

it is essential to acknowledge the ongoing challenges associated with its acceptance and limited compliance (17). Anti-inflammatory therapy as a combination of montelukast and intranasal steroid was also shown to improve AHI and oxygen nadir in children with mild OSA following AT (18). Finally, weight control should be suggested for children who are dealing with overweight or obesity. In the NANOS study (19), half of the obese children with mild OSA, who did not have adenotonsillar hypertrophy and were treated with dietary changes to promote weight reduction, showed improvement in OSA during the follow-up. In other retrospective analysis, Tholen et. al. (20) showed that obese children had more severe OSA in the supine position after AT. In this group of patients positional therapy may be a viable alternative treatment option.

A detailed description of specific surgeries goes beyond the scope of this article but in this context, it is worth distinguishing between ATE and ATT in treating OSA in children. In many countries, including Poland, ATT or intracapsular tonsillectomy (in contrary to ATE, or extracapsular tonsillectomy) is more widely performed in children with tonsillar hypertrophy. Although several systematic reviews (21-23) have concluded that adenotonsillectomy ATT have similar effect on OSA symptoms as ATE, it may also be associated with the risk of tonsillar tissue regrowth, especially when performed in younger children (24). The risk of OSA relapse after ATT should be taken into account in persistent OSA child and we should bare in mind that patients undergoing ATT may need ATE in order to resolve persistent OSA.

Ultimately, management of patients with persistent OSA should be made through a thorough evaluation by a multidisciplinary team, taking into account all relevant clinical information, in order to find the best treatment for patient, which is essential for the successful management of chronic diseases such as OSA.

CONCLUSIONS

A significant number of children suffer from persistent OSA post-AT. Risk factors for residual OSA include obesity, severe OSA pre-AT, certain age, and concurrent underlying medical conditions, such as Down syndrome. Children should be assessed post-AT for persisting symptoms and PSG should be routinely performed in those at high risk. In persistent OSA patients, visualization of the airway using DISE or cine MRI, to identify sites of obstruction, can allow more directed interventions. There is a diverse range of available and emerging surgical and non-surgical therapeutic options used to treat persistent OSA. The care of such children should be integrated into a multidisciplinary team management approach involving different medical specialties.

CONFLICT OF INTEREST KONFLIKT INTERESÓW

None
Brak konfliktu interesów

REFERENCES/PIŚMIENNICTWO

1. DelRosso LM: Epidemiology and Diagnosis of Pediatric Obstructive Sleep Apnea. *Curr Probl Pediatr Adolesc Health Care* 2016; 46(1): 2-6.
2. Mitchell RB, Kelly J: Behavior, neurocognition and quality-of-life in children with sleep-disordered breathing. *Int J Pediatr Otorhinolaryngol* 2006; 70(3): 395-406.

CORRESPONDENCE
ADRES DO KORESPONDENCJI

*Lidia Zawadzka-Głós
Klinika Otolaryngologii Dziecięcej
Warszawski Uniwersytet Medyczny
ul. Żwirki i Wigury 63A, 02-091 Warszawa
tel.: +48 (22) 317-97-21
laryngologia.dsk@uckwum.pl

- Lis T, Zawadzka-Głós L: Diagnosis and evaluation of a child suspected for obstructive sleep apnea: an overview. *New Medicine* 2020; 3: 87-91.
- Lis T, Zawadzka-Głós L: Treatment and management of a child with obstructive sleep apnea: an overview. *New Medicine* 2021; 3: 87-90.
- Ishman SL, Maturo S, Schwartz S et al.: Expert Consensus Statement: Management of Pediatric Persistent Obstructive Sleep Apnea After Adenotonsillectomy. *Otolaryngol Head Neck Surg* 2023; 168(2): 115-130.
- Ersu R, Chen ML, Ehsan Z et al.: Persistent obstructive sleep apnoea in children: treatment options and management considerations. *Lancet Respir Med* 2023; 11(3): 283-296.
- Marcus CL, Brooks LJ, Draper KA et al.: Diagnosis and management of childhood obstructive sleep apnea syndrome. *Pediatrics* 2012; 130(3): e714-55.
- Imanguli M, Ulualp SO: Risk factors for residual obstructive sleep apnea after adenotonsillectomy in children. *Laryngoscope* 2016; 126(11): 2624-2629.
- Shete MM, Stocks RM, Sebelik ME, Schoumacker RA: Effects of adeno-tonsillectomy on polysomnography patterns in Down syndrome children with obstructive sleep apnea: a comparative study with children without Down syndrome. *Int J Pediatr Otorhinolaryngol* 2010; 74(3): 241-244.
- Lee CH, Hsu WC, Ko JY et al.: Adenotonsillectomy for the Treatment of Obstructive Sleep Apnea in Children with Prader-Willi Syndrome: A Meta-analysis. *Otolaryngol Head Neck Surg* 2020; 162(2): 168-176.
- Gönültaş B, Yılmaz T, Sivri HS et al.: Mucopolysaccharidosis: Otolaryngologic findings, obstructive sleep apnea and accumulation of glucosaminoglycans in lymphatic tissue of the upper airway. *Int J Pediatr Otorhinolaryngol* 2014; 78(6): 944-949.
- Kirk V, Baughn J, D'Andrea L et al.: American Academy of Sleep Medicine Position Paper for the Use of a Home Sleep Apnea Test for the Diagnosis of OSA in Children. *J Clin Sleep Med* 2017; 13(10): 1199-1203.
- Kaditis AG, Alonso Alvarez ML, Boudewyns A et al.: Obstructive sleep disordered breathing in 2- to 18-year-old children: diagnosis and management. *Eur Respir J* 2016; 47(1): 69-94.
- Bitners AC, Arens R: Evaluation and Management of Children with Obstructive Sleep Apnea Syndrome. *Lung* 2020; 198(2): 257-270.
- Aurora RN, Zak RS, Karippot A et al.: Practice parameters for the respiratory indications for polysomnography in children. *Sleep* 2011; 34(3): 379-388.
- Socarras MA, Landau BP, Durr ML: Diagnostic techniques and surgical outcomes for persistent pediatric obstructive sleep apnea after adenotonsillectomy: A systematic review and meta-analysis. *Int J Pediatr Otorhinolaryngol* 2019; 121: 179-187.
- Uong EC, Epperson M, Bathon SA, Jeffe DB: Adherence to nasal positive airway pressure therapy among school-aged children and adolescents with obstructive sleep apnea syndrome. *Pediatrics* 2007; 120(5): e1203-1211.
- Kheirandish L, Goldbart AD, Gozal D: Intranasal steroids and oral leukotriene modifier therapy in residual sleep-disordered breathing after tonsillectomy and adenoidectomy in children. *Pediatrics* 2006; 117(1): e61-66.
- Alonso-Álvarez ML, Cordero-Guevara JA, Terán-Santos J et al.: Obstructive sleep apnea in obese community-dwelling children: the NANOS study. *Sleep* 2014; 37(5): 943-949.
- Tholen K, Meier M, Kloor J, Friedman N: Persistent OSA in obese children: does body position matter? *J Clin Sleep Med* 2021; 17(2): 227-232.
- Borgström A, Nerfeldt P, Friberg D: Adenotonsillectomy versus adenotonsillectomy in pediatric obstructive sleep apnea: A 5-year RCT. *Sleep Med X* 2022; 4: 100055.
- Kim JS, Kwon SH, Lee EJ, Yoon YJ: Can Intracapsular Tonsillectomy Be an Alternative to Classical Tonsillectomy? A Meta-analysis. *Otolaryngol Head Neck Surg* 2017; 157(2): 178-189.
- Zhang LY, Zhong L, David M, Cervin A: Tonsillectomy or tonsillotomy? A systematic review for paediatric sleep-disordered breathing. *Int J Pediatr Otorhinolaryngol* 2017; 103: 41-50.
- Borgström A, Nerfeldt P, Friberg D et al.: Trends and changes in paediatric tonsil surgery in Sweden 1987-2013: a population-based cohort study. *BMJ Open* 2017; 7(1): e013346.

submitted/nadesłano:

1.02.2023

accepted/zaakceptowano do druku:

22.02.2023